

Erythema multiforme following Orf viral infection: a comprehensive review of the literature with a case report highlight

Mona Alkallabi,¹ Khalid Nabil Nagshabandi,¹ Shaden Alobaid,¹ Reem Bin Idris,¹ Amany Fathaddin²

¹Department of Dermatology, College of Medicine, King Saud University Medical City, Riyadh; ²Department of Pathology, College of Medicine, King Saud University, Riyadh, Saudi Arabia

Abstract

Orf, also known as ecthyma contagiosum, is a highly contagious zoonotic infection linked to direct contact with infected sheep, goats, or reindeer, posing a significant risk to farmers, veterinarians, shepherds, and butchers. This study presents a case of a 41-year-old female who developed Orf, complicated by the rare occurrence of erythema multiforme (EM), after handling sheep meat. The patient initially presented with a

progressive, painful skin eruption on the left dorsum of the little finger, which subsequently worsened and led to the development of generalized painful and itchy skin lesions, including target lesions typical of EM, on the palms, soles, and extremities. The diagnosis was confirmed through clinical examination and skin biopsy. The patient was treated with antihistamines and topical corticosteroids, resulting in a complete resolution of symptoms within three weeks. We underscore the importance of recognizing EM as a potential complication of Orf infection, particularly in individuals with occupational animal exposure.

Correspondence: Khalid Nabil Nagshabandi, Department of Dermatology, College of Medicine, King Saud University Medical City, Riyadh, Saudi Arabia.
E-mail: khaloed23@gmail.com

Key words: Orf virus; parapoxvirus; contagious pustular dermatitis/ecthyma; erythema multiforme; case report.

Contributions: All authors made a significant intellectual contribution. Each author has read and approved the final version of the manuscript and agrees to be held accountable for all aspects of the work.

Conflict of interest: the authors declare no potential conflict of interest.

Ethics approval and consent to participate: in accordance with local or national guidelines, ethical approval is not required for this study.

Consent for publication: the patient gave written informed consent for the publication of her medical case details and any accompanying images.

Availability of data and materials: all data generated or analyzed during this study are included in this article. Further inquiries can be directed to the corresponding author.

Received: 28 April 2024.
Accepted: 5 September 2024.

This work is licensed under a Creative Commons Attribution-NonCommercial 4.0 International License (CC BY-NC 4.0).

©Copyright: the Author(s), 2024
Licensee PAGEPress, Italy
Dermatology Reports 2025; 17:10032
doi:10.4081/dr.2024.10032

Publisher's note: all claims expressed in this article are solely those of the authors and do not necessarily represent those of their affiliated organizations, or those of the publisher, the editors and the reviewers. Any product that may be evaluated in this article or claim that may be made by its manufacturer is not guaranteed or endorsed by the publisher.

Introduction

Orf, or ecthyma contagiosum, is a highly contagious zoonotic viral infection. It is associated with exposure to sheep, goats, or reindeer. Transmission to humans occurs through direct contact with infected lesions on said animals or through contaminated fomites. Farmers, veterinarians, shepherds, and butchers are the most at-risk populations. The infections may be encountered in Islamic countries following Eid Al-Adha's Feast of Sacrifice. During this time, presentations may be confused with anthrax.¹

It typically presents as an asymptomatic lesion on the hand. Over the course of 6-8 weeks, the lesion progresses through 6 clinical stages: maculopapular, target, acute-nodular weepy, regenerative-nodular dry, papilloma, and regression stages, assuming different morphologies with each stage.² Though histology can be used to confirm the diagnosis, a clinical diagnosis is usually sufficient. The disease is self-limiting in immunocompetent patients. However, it can be complicated by erythema multiforme (EM) through a secondary immune reaction. Here, we report a case of Orf viral infection complicated with EM and review the previously reported instances in the literature.

Case Report

A 41-year-old female presented to the Emergency Department complaining of progressive painful skin eruption over the left dorsum of the little finger for two weeks. Her past medical and surgical history was significant for iron deficiency anemia, sleeve gastrectomy, and cholecystectomy.

After delving deeper into the eruption history, the patient conveyed that it started two weeks before her presentation and after inadvertently lacerating her two little fingers with sheep teeth while she was handling sheep meat. One week after the incident, her skin eruption worsened and was draining some fluid. After the deterioration of her condition, she decided to seek assistance at the primary health care clinic, and augmentin 625 mg TID for 3 days was prescribed. After administering augmentin, the patient reported a generalized painful and itchy skin eruption over her trunk and extremities on the same day of starting therapy,

prompting her to discontinue the medication. A dermatologic examination of the lesion showed a solitary erythematous nodule that was covered with hemorrhagic crust and surrounded by a well-defined, erythematous, hot, indurated, tender plaque on her right little finger (erysipeloid reaction). In addition, the right ring finger showed a longitudinal hemorrhagic crust (healed nodule). Furthermore, there were generalized, well-defined, light pink urticated papules and plaques (Figure 1). Some of them exhibited the appearance of target lesions on her palms and soles bilaterally. Multiple light pink macules and patches with scratch marks were noticed over the forearms, arms, thighs, legs (Figures 2 and 3), upper chest, and buttock area. No ocular, oral, genital, or mucous membrane involvement was noted. The left dorsum of the hand exhibited signs of swelling, tenderness, edema, and hotness, especially when compared to the contralateral limb up to the elbows (erysipelas reaction). Considering all aforementioned clinical characteristics, the presentation is suggestive of Orf complicated by EM minor.

For the diagnostic workup, left-hand X-ray and magnetic resonance imaging (MRI) yielded negative results and ruled out osteomyelitis. Additionally, one 4 mm punch skin biopsy was taken from the eruption site in the leg to rule out drug eruption from amoxicillin/clavulanic acid. Microscopic examination of the hematoxylin and eosin (H&E)-stained tissue sections from the skin punch biopsy revealed mild dermal edema, dilatation of small blood vessels, and mild perivascular lymphocytic infiltrate (Figure 4). Skin biopsy from left little finger for H&E and tissue culture with viral PCR were not taken due to patient refusal because of pain.

Regarding the treatment plan, she was prescribed antihistamine (loratadine 10 mg daily and chlorpheniramine 4 mg HS) and topical mometasone furoate 0.1% ointment to be applied on all skin lesions. She was also prescribed to apply topical imiquimod 5% cream on the left little finger nodule three times a week and cover the lesion with mepilex AG dressing. In addition, the patient was instructed to clean the left index finger with normal saline daily and apply urea topical cream on all skin eruptions or vaseline ointment twice daily. Upon follow-up in the clinic after 3 weeks, the eruption subsided, and outcomes were favorable (Figure 5).

Discussion

Orf, alternatively referred to as ecthyma contagiosum or contagious pustular dermatitis, is a viral infection that predominantly affects individuals engaged in occupations such as farming, shepherding, veterinary medicine, and butchery due to occupational exposure.³ It is attributed to an epitheliotropic, double-stranded DNA virus belonging to the Parapoxvirus genus within the Poxviridae family.³ Orf presents with singular or multiple nodules typically observed on the hands and fingers but can also manifest on the feet, legs, neck, and face. Following an incubation period lasting 3-7 days, the lesions progress through six distinct clinical stages: i) maculopapular stage (days 1-7), characterized by erythematous macules or papules; ii) target stage (days 7-14), featuring a necrotic center surrounded by a red outer halo; iii) acute stage (days 14-21), marked by the onset of nodular weeping; iv) regenerative stage (days 21-28), during which the nodule begins to dry; v) papilloma stage (days 28-35), where the lesion adopts a papilloma-like appearance and forms a dry crust; vi) regression stage (after 35 days).⁴

Orf-induced lesions may be accompanied by symptoms such as lymphangitis, lymphadenopathy, malaise, fever, and erysipelas

as a secondary bacterial infection.⁵ Uncommon occurrences of papulovesicular eruptions have been documented, including a bullous pemphigoid-like eruption.⁶ The immune reaction triggered by Orf infection is believed to be accountable for EM.⁷ However, the occurrence of EM subsequent to Orf infection is uncommon and rare. Our case reports a 41-year-old female who developed an Orf infection complicated by the rare occurrence of EM minor lesions.

To the best of our knowledge, a total of 43 cases, including the

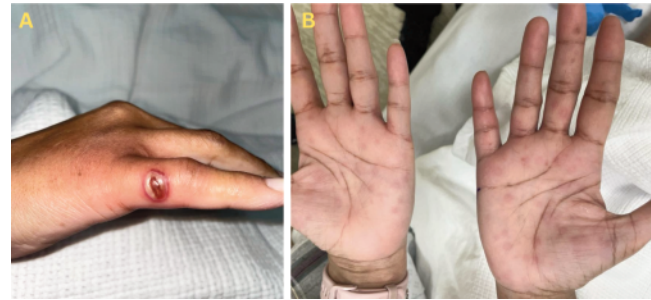

Figure 1. A) A single well-demarcated erythematous inflammatory nodule covered with a hemorrhagic crust that is surrounded by a clear, erythematous, tender plaque on the little finger; **B)** generalized well-defined light pink urticated papules and plaques on the palms of both hands (bilateral).

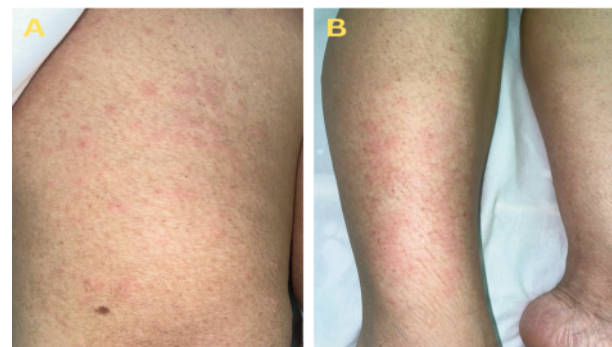


Figure 2. A,B) Multiple well-defined light pink macules and patches, with some exhibiting urticated plaques over the thighs and legs.

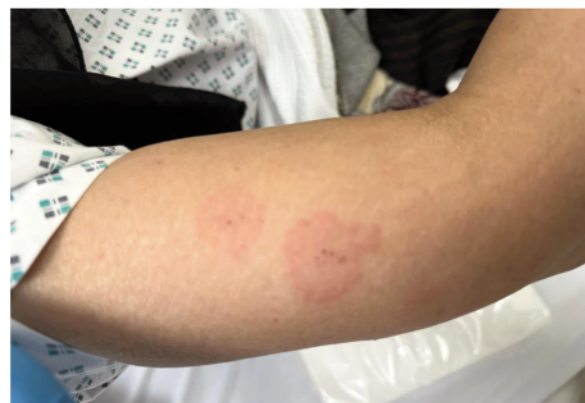

Figure 3. Two well-defined pale pink macules, accompanied by scratch marks on both sides, over the forearms.

one documented herein, have been reported to acquire EM post-Orf viral infection. A summary review and comparison of documented occurrences of EM associated with Orf infection from oldest to most recent are provided in Supplementary Table 1.⁸⁻²⁷ Out of all cases reported, twenty-three patients were females, and sixteen were males, with the ages ranging from 6 to 56 years. A total of twenty-one patients documented specific exposure to animals, predominantly sheep in ten cases, lamb in five cases, goat in three cases, and calf in one case, as well as interactions with raw meat in six cases. Regarding the diagnostic approach, in most instances, the final diagnosis was established with clinical cutaneous examination only in twenty-eight cases. A combined clinical exam and skin biopsy of lesions were employed in twelve cases. Treatment approaches for Orf-induced EM vary, with five cases managed conservatively with no specific intervention. Topical corticosteroids were utilized in ten cases. Two cases showed no response or resistance to topical steroids and were managed with topical imiquimod as the next step approach. In more severe cases with further complicated painful lesions, oral

and intravenous antibiotics for secondary superimposed bacterial infection, oral corticosteroids, cetirizine, antihistamines, and intravenous corticosteroids were employed.

Orf infection typically presents as a benign, self-limiting condition, usually resolving spontaneously within 6 to 8 weeks without lasting effects. In the majority of cases, symptomatic treatment suffices, advising patients to maintain lesion cleanliness with local antiseptics, initially using moist dressings and later transitioning to dry ones.²⁴ If a concurrent bacterial infection is suspected, appropriate topical or systemic antibiotic therapy may be considered. Various treatment modalities have been proposed, such as surgical excision, cryotherapy, and the topical application of immune-response modulators like corticosteroids and imiquimod or antiviral agents like cidofovir. Despite these options, there is insufficient evidence to recommend any specific treatment.¹⁴ The impact of the Orf virus extends widely across global health, environmental, and economic domains, notably affecting the agricultural sector. While human Orf infections are commonly identified among animal handlers such as veterinarians and farm laborers, physicians may also encounter characteristic lesions in individuals engaged in specific cultural rituals, such as the traditional animal sacrifice associated with the Muslim holiday Eid al-Adha. Overall, this case highlights the importance of recognizing Orf infection and its potential complications, particularly in individuals with occupational or cultural exposures. Clinicians should maintain a high index of suspicion for Orf in patients presenting with characteristic skin lesions, especially in settings where animal contact is prevalent.

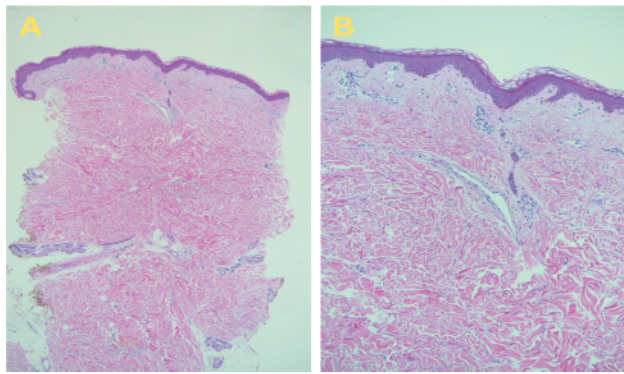


Figure 4. Skin biopsy showed mild dermal edema, dilatation of small blood vessels and mild perivascular lymphocytic infiltrate. **A)** H&E, original magnification x4; **B)** H&E, original magnification x10.

Conclusions

Despite its rarity, the occurrence of EM following Orf infection underlines the need among clinicians for awareness and recognition of this potential complication. This awareness is crucial for prompt and appropriate management, especially considering the broad differential diagnosis that includes other zoonotic infections.

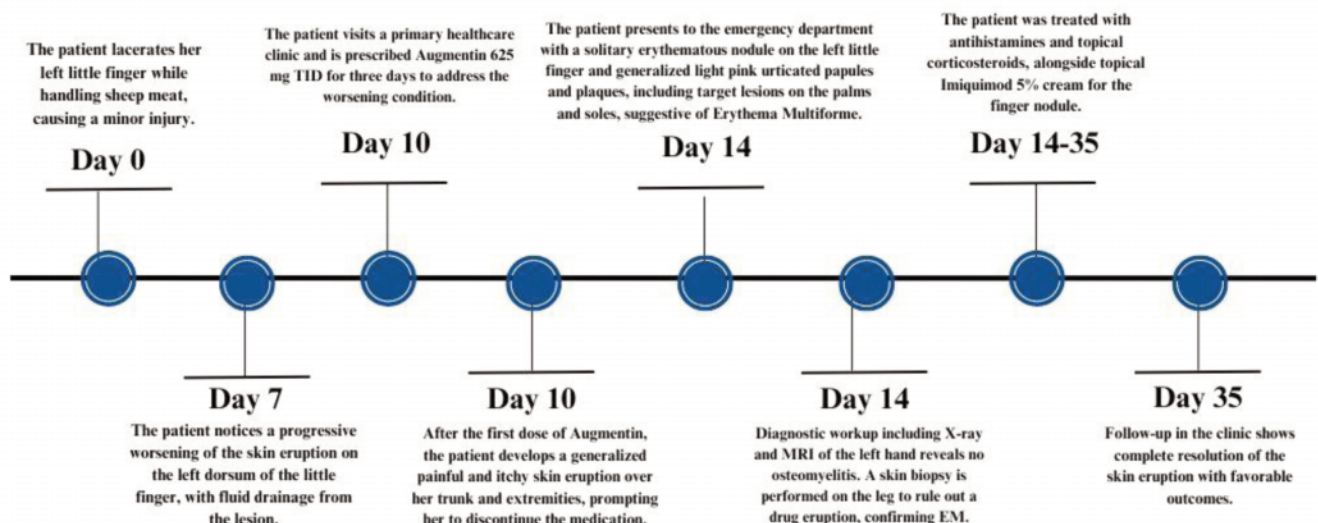


Figure 5. Case timeline of events.

References

- Adams B. Human Orf complicated with erythema multiforme. *Int J Dermatol* 2008;47:1334-6.
- Bolognia JL. *Dermatology* Philadelphia, USA: Elsevier Saunders; 2012.
- Joseph RH, Haddad FA, Matthews AL, et al. Erythema multiforme after Orf virus infection: a report of two cases and literature review. *Epidemiol Infect* 2015;143:385-90.
- Al-Qattan MM. Orf infection of the hand. *J Hand Surg Am* 2011;36:1855-8.
- Diven DG. An overview of poxviruses. *J Am Acad Dermatol* 2001;44:1-16.
- White KP, Zedek DC, White WL, et al. Orf-induced immunobullous disease: a distinct autoimmune blistering disorder. *J Am Acad Dermatol* 2008;58:49-55.
- Schmidt E, Weissbrich B, Bröcker EB, et al. Orf followed by erythema multiforme. *J Eur Acad Dermatol Venereol* 2006;20:612-3.
- Johannessen JV, Krogh HK, Solberg I, et al. Human Orf. *J Cutan Pathol* 1975;2:265-83.
- Agger WA, Webster SB. Human Orf infection complicated by erythema multiforme. *Cutis* 1983;31:334-8.
- Bassioukas K, Orfanidou A, Stergiopoulou CH, Hatzis J. Orf. Clinical and epidemiological study. *Australas J Dermatol* 1993;34:119-23.
- Erbağci Z, Erbağci I, Almila Tuncel A. Rapid improvement of human Orf (ecthyma contagiosum) with topical imiquimod cream: report of four complicated cases. *J Dermatolog Treat* 2005;16:353-6.
- Schmidt E, Weissbrich B, Bröcker EB, et al. Orf followed by erythema multiforme. *J Eur Acad Dermatol Venereol* 2006;20:612-3.
- Coskun O, Gul CH, Bilgeturk A, et al. Human Orf complicated with erythema multiforme. *Int J Dermatol* 2008;47:1333-4.
- de Wet C, Murie J. Lamb pays lip service: two cases of ecthyma contagiosum (Orf). *Scott Med J* 2011;56:59.
- Ozturk P, Sayar H, Karakas T, Akman Y. Erythema multiforme as a result of Orf disease. *Acta Dermatovenereol Alp Pannonica Adriat* 2012;21:45-6.
- Durdu M, Ruocco V. Clinical and cytologic features of antibiotic-resistant acute paronychia. *J Am Acad Dermatol* 2014;70:120-6.e1.
- Shahmoradi Z, Abtahi-Naeini B, Pourazizi M, Meidani M. Orf Disease Following "Eid ul-Adha": A Rare Cause of Erythema Multiforme. *Int J Prev Med* 2014;5:912-4.
- Yorulmaz A, Artüz Rf, Yayla Yg, Kayaçetin S. A Case of Human Orf Complicated with Atypical Erythema Multiforme. *Türkiye Klinikleri J Dermatol* 2014;24:115-8.
- Gallina L, Veronese F, Farinelli P, et al. Erythema multiforme after Orf virus infection. *Epidemiol Infect* 2016;144:88-9.
- Alian S, Ahangarkani F, Arabsheybani S. A Case of Orf Disease Complicated with Erythema Multiforme and Bullous Pemphigoid-Like Eruptions. *Case Rep Infect Dis* 2015;2015:105484.
- Biazar T, Shokri M, Hosseinnia H, Bayani M. Erythema Multiforme as a Result of Orf Disease; a Case Report. *Emerg (Tehran)* 2016;4:163-5.
- Maman M, Medhioub Y. Ecthyma contagiosum compliqué d'érythème polymorphe: à propos d'un cas. *Archives de Pédiatrie* 2017;24:1241-3.
- López-Cedeño A, Cañedo G, Knöpfel N, et al. Erythema multiforme after Orf virus infection. *Pediatr Dermatol* 2018;35:e237-8.
- Khouana A, Bazouti S, Zerrouki N, et al. Multiforme erythema complicating an Orf. *Our Dermatol Online* 2019;10:68-70.
- Wu K, de Menezes S, Robinson A. Erythema Multiforme Induced by a "Milker's Nodule" Pseudocowpox Infection: A Case Report and Review of Literature. *Case Rep Dermatol Med* 2021;2021:5584773.
- Cavalieri C, Dupond AS, Ferrier-Rembert A, et al. Orf Nodule with Erythema Multiforme during a Monkeypox Outbreak, France, 2022. *Emerg Infect Dis* 2023;29:860-2.
- Salvi M, Tiecco G, Rossi L, et al. Finger nodules with a papulovesicular hands and feet eruption: a complicated human Orf virus infection. *BMC Infect Dis* 2024;24:95.

Online Supplementary Material:

Supplementary Table 1. Summary review of reported cases involving erythema multiforme triggered by Orf-viral infection.