

# Melanoma in pregnancy: multidisciplinary treatment management and outcome

Francesca Romana Grippaudo,<sup>1</sup> Giulia Ruggeri,<sup>1</sup> Paola De Simone,<sup>2</sup> Monia Di Prete,<sup>3</sup> Guglielmo Tellan,<sup>4</sup> Elena Rita Govoni,<sup>5</sup> Emilia Migliano<sup>6</sup>

<sup>1</sup>Department of Plastic Surgery, Policlinico Umberto I, Sapienza University of Rome; <sup>2</sup>Dermatological Oncology, San Gallicano Dermatological Institute IRCCS, Rome; <sup>3</sup>Dermatopathology Unit, San Gallicano Dermatological Institute IRCCS, Rome; <sup>4</sup>Department of Internistic, Anaesthetic and Cardiovascular Clinical Sciences, Sapienza University of Rome; <sup>5</sup>Medicine and Surgery, Campus Bio-Medico University of Rome; <sup>6</sup>Plastic and Regenerative Surgery Department, San Gallicano Dermatological Institute IRCCS, Rome, Italy

## Abstract

Pregnancy-associated melanoma affects both maternal and fetal health. This study aims to demonstrate how a specialized center and a multidisciplinary approach can provide the best outcomes. From January 2006 to September 2023, a bicentric obser-

vatational study was conducted at the Plastic Surgery Department of Policlinico Umberto I, Sapienza University of Rome, and at the Plastic and Regenerative Surgery Department of the San Gallicano Dermatological Institute IRCCS, Rome, Italy. Out of 6,800 melanoma cases, twenty pregnant women were selected: thirteen underwent only wide local excision (WLE), while seven also had sentinel node biopsy (SLNB). All preoperative, operative, and postoperative steps were performed to ensure the safety of mothers and fetuses. Two patients developed metastases, with one fatality from hepatic metastases. At 5-year follow-up overall survival was 86%, while disease-free survival in advanced-stage melanoma patients was 72%. No maternal or fetal complications related to surgery were reported. Additionally, early deliveries at 7 and 8 months did not result in neonatal complications. Surgical treatment should be conducted in centers with both surgeons and gynecologists, and special care is necessary for procedures on pregnant women. Based on our experience, pregnancy does not seem to be a negative prognostic factor for melanoma.

Correspondence: Giulia Ruggeri, MD, Department of Plastic Surgery, Policlinico Umberto I, Sapienza University of Rome, viale del Policlinico 155, 00161 Rome, Italy.  
E-mail: giulia.ruggeri@uniroma1.it  
Tel.: +39.3342200772.

Key words: melanoma; pregnancy; skin cancer; sentinel lymph node biopsy; survival.

Conflict of interest: the authors declare that they have no competing interests.

Ethics approval and consent to participate: this study has been authorized by the ethical committee "Comitato Etico Centrale IRCCS Lazio, Sezione IRCCS IFO – Fondazione G.B. Bietti." Protocol number 15483, 05/12/2023 – IFO\_AOO – AOO – IFO Reg. Sperim. N. 62/ISG/23.

Availability of data and materials: all data generated or analyzed during this study are included in this published article and come from an institutional database.

Funding: this research was funded by the Scientific Direction of IRCCS San Gallicano Dermatological Institute, financed by the Ministry of Italian Health.

Received: 25 July 2024.  
Accepted: 5 January 2025.

This work is licensed under a Creative Commons Attribution-NonCommercial 4.0 International License (CC BY-NC 4.0).

©Copyright: the Author(s), 2025  
Licensee PAGEPress, Italy  
Dermatology Reports 2025; 17:10095  
doi:10.4081/dr.2025.10095

*Publisher's note: all claims expressed in this article are solely those of the authors and do not necessarily represent those of their affiliated organizations, or those of the publisher, the editors and the reviewers. Any product that may be evaluated in this article or claim that may be made by its manufacturer is not guaranteed or endorsed by the publisher.*

## Introduction

Melanoma is a malignant skin cancer, and its incidence is rapidly increasing worldwide. According to Italian Association of Medical Oncology (AIOM) guidelines, 85% of cases occur in North America, Europe, and Oceania, and skin melanoma is one of the most common cancers that presents in young people<sup>1</sup>

Some studies report that one-third of female patients who develop melanoma are of childbearing age.<sup>2</sup> The overall incidence is approximately 1/1,000 pregnancies.

Pregnancy-associated melanoma (PAM) is defined as a melanoma diagnosed during pregnancy or in the first year postpartum.<sup>3</sup> Among all the pregnancy-related cancers, melanoma of the skin is the most frequently diagnosed when compared to breast, thyroid, or gynecological cancers.<sup>2,4</sup> This condition needs a multidisciplinary team approach, where dermatologists, plastic surgeons, oncologists, anesthesiologists, obstetric gynecologists, neonatologists, pathologists, and radiologists play a fundamental role in order to guarantee personalized therapeutic planning to treat cancer without harming the fetus and the mother.

Multiple factors seem to adversely affect the possibility of developing melanoma and its eventual course during pregnancy.<sup>2</sup> The skin shows an increased risk of hyperpigmentation, for example, of the mammary areola and pre-existent nevi, due to the increase in progesterone levels during gestation, which has as a side effect the overproduction of melanin.

Recent studies document transient clinical-dermatoscopic changes of melanocytic nevi during pregnancy. Consequently, a close follow-up of pigmented lesions, both clinical and instrumen-

tal, is advised during pregnancy, and care must be taken to reveal the presence of other risk factors for melanoma.<sup>5</sup> However, follow-up is often neglected, causing delays in diagnosis.

Tumor lymphangiogenesis has been described as the strongest independent predictor of sentinel lymph node (SLN) invasion from melanoma metastases.<sup>6,7</sup> Moreover, hormone effects, immunological changes, and lymphangiogenesis have been examined in terms of their possible impact on melanoma development and progression. Still, none of them has been proven to be an independent risk factor.<sup>8</sup>

Literature on the mortality of pregnancy-related melanoma is still contradictory. Despite several studies showing that prognosis is similar when pregnant and non-pregnant women are affected by similar stages of melanoma,<sup>9,10</sup> debate is still ongoing.

In the management of pregnancy-related melanoma, the tumoral stage and the gestational period must be taken into account, as well as the will of the child-bearing mother, properly and fully informed. Procrastination of the treatment until after partum may be responsible for a poorer prognosis. In selected cases, anticipating partum may be advised to proceed with more invasive surgical procedures or oncological treatments.

## Materials and Methods

From January 2006 to March 2023, a bicentered observational study that involved the Plastic Surgery Department of Policlinico Umberto I, Sapienza University of Rome and the Plastic and Regenerative Surgery Department of the San Gallicano Dermatological Institute IRCCS (Rome, Italy) was carried out.

The inclusion criteria were gestational age from the 1<sup>st</sup> month of pregnancy to the 12<sup>th</sup> month postpartum, melanoma stage 0, pT1, pT2, pT3, and pT4, and a follow-up completed at 5 years.

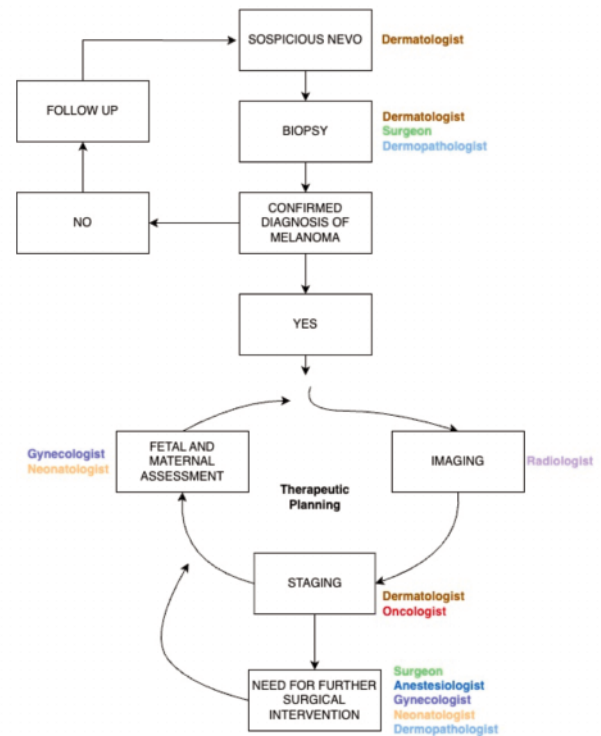
Twenty pregnant women were enrolled; thirteen underwent wide local excision (WLE), and seven underwent WLE and sentinel node biopsy (SLNB). Four received diagnoses during the first trimester, six during the second trimester, and ten during the third trimester (Table 1).

Multidisciplinary team treatment was crucial: plastic surgeons, dermatologists, oncologists, anesthesiologists, obstetric gynecologists, neonatologists, pathologists, and radiologists were involved. Psychological support was offered to each patient, and

pregnant patients were included in every medical decision. The surgical treatments were performed according to the AIOM guidelines.<sup>1</sup>

The patients in the first and second trimester who needed WLE and SLNB waited for the third trimester to safely undergo lymphoscintigraphy. After the first trimester of gestational age, 99mTc lymphoscintigraphy is considered a safe procedure in pregnancy. Methylene blue is instead avoided because of its teratogenic effects.<sup>1</sup>

After a multidisciplinary discussion of the cases, early deliv-



**Figure 1.** Therapeutic planning and specialized medical figures involved.

**Table 1.** Patients receiving WLE only.

Case	Age	Site	Trimester	Histotype	Breslow mm	Stage	5-years follow-up
1	35	Trunk	III	SSM	In situ	pTis	alive
2	34	Trunk	III	SSM	0,4	pT1a	alive
3	29	Trunk	III	SSM	0,7	pT1a	alive
4	30	Leg	I	SSM	0,7	pT1a	alive
5	33	Trunk	III	SSM	0,5	pT1a	alive
6	28	Leg	II	SSM	0,6	pT1a	alive
7	40	Trunk	III	SSM	0,4	pT1a	alive
8	38	Leg	II	SSM	0,5	pT1a	alive
9	35	Leg	III	SSM	0,6	pT1a	alive
10	32	Chest	III	SSM	0,5	pT1a	alive
11	38	Trunk	II	SSM	In situ	pTis	alive
12	33	Arm	I	SSM	0,4	pT1a	alive
13	39	Leg	I	SSM	0,4	PT1a	alive

WLE, wide local excision; SSM, superficial spreading melanoma.

ery at the 7<sup>th</sup> month was decided for one patient with pT3aN1. Early delivery at the 8<sup>th</sup> month was carried out for two patients with pT2aN1M1 and pT4aN0.

Blood tests, electrocardiograms, and lymph node echography were performed before the surgery was planned. Pregnant patients underwent anesthesiologic, gynecological, neonatological, and surgical preoperative medical examinations to properly assess the maternal and fetal risks.

Vitals (arterial pressure, saturation) were constantly monitored. The gynecologist was paged in the operating theater before the surgery to perform cardiac fetal monitoring, which was repeated at the end of the procedure. When possible, the patients were positioned in the lateral left tilt position to avoid aortocaval compression syndrome. When the surgical procedure was WLE, local anesthesia with lidocaine was performed by surgeons under anesthesiologic supervision. When SLNB had to be performed, a new anesthesiologic evaluation was carried out to decide the best anesthesia procedure (general anesthesia, spinal anesthesia, nerve block). Antibiotic perioperative administration was performed using penicillin-based derivatives and cephalosporins; none of the enrolled patients reported drug allergies.

Figure 1 summarizes the therapeutic planning and specialized medical figures involved.

## Results

The median maternal age was 34.1 for patients shown in Table 1 and 31.6 for patients shown in Table 2. In 50% of patients, melanoma was diagnosed in the third trimester of pregnancy, in 30% of patients in the second trimester, and in 20% of patients in the first trimester.

Intraoperative maternal complications, intraoperative fetal complications, and maternal-fetal complications strictly related to surgery were evaluated in this study.

In this sample, general, spinal, or local anesthesia did not cause intraoperative maternal complications, and no significant variation in vital parameters of the mother was detected.

Fetal abnormalities were not detected preoperatively or postoperatively: fetal heart rate monitoring was normal before and after surgery in every patient. No fetal distress was identified when further investigations were requested by obstetric gynecologists (such as ultrasounds). There were no maternal-fetal complications strictly related to surgery.

In our cases, early delivery, at the 7<sup>th</sup> and 8<sup>th</sup> month, did not cause any problems for the newborns, who had already reached an acceptable weight and did not need further neonatal intensive assistance. Data from the database of San Gallicano

Dermatological Institute Plastic Surgery on melanoma patients reports 6,800 cases: only twenty patients were pregnant, and only seven of those underwent SNL. The median age of the pregnant women was 31.6 years. The median gestational age at diagnosis was 6 months. Overall survival at 5-year follow-up is 86%, but if we consider only advanced melanoma stages, disease-free survival is 72%. Two cases have been found positive to SNL biopsy, and only two patients metastasized; of them, only one died from hepatic metastases (Table 2).

## Discussion

Breast cancer, melanoma, and thyroid cancers are the most frequently diagnosed during pregnancy;<sup>11</sup> therefore, it is not an infrequent condition for a plastic surgeon to face.

PAM represents a critical clinical situation, both for cancer diagnosis and pregnancy, as it involves numerous complex clinical and ethical decisions.

Oncologic and surgical management of pregnant women should take into account the patient's desire; it should weigh maternal and fetal risks, well-being, and optimal treatment. Termination of pregnancy can be evaluated when aggressive and advanced cancer is diagnosed in early pregnancy; preterm induction should be avoided when possible.<sup>12</sup>

According to old literature, PAM was considered to have a worse prognosis compared to melanoma diagnosis in non-pregnant women.<sup>13</sup> Recent studies show there is enough evidence suggesting that pregnancy does not affect melanoma risk and survival.<sup>5,14</sup>

In earlier studies, disease-free survival or thickness did not show significant differences when a localized invasive melanoma was diagnosed.<sup>15</sup>

A recent meta-analysis questioned whether a subsequent pregnancy after being diagnosed with melanoma could negatively affect the prognosis: findings do not suggest that, but further studies are needed.<sup>16</sup>

## Treatment considerations

Ultrasounds, chest X-rays with appropriate shields, and magnetic resonance, preferably without gadolinium, can be performed to complete tumoral staging.<sup>17</sup>

Once the cancer stage is assessed, surgical treatment has to be planned. According to the American Joint Committee on Cancer (AJCC), the European Society for Medical Oncology (ESMO), and AIOM guidelines, wide excision is always indicated. SLNB is indicated when the histological report is pT1b.<sup>1</sup> Dermatologists or surgeons can proceed safely in any trimester when a biopsy has to

**Table 2.** Patients receiving WLE + SLNB.

Case	Age	Site	Trimester	Histotype	Breslow mm	Stage	5-years follow-up
1	29	Trunk	II	SSM	0,9	pT1bN0	alive
2	28	Leg	II	SSM	1	pT2a N0	alive
3	27	Leg	III	SSM	1	pT2aN0	alive
4 A*	32	Trunk	II	NM	1,2	pT2aN1M1	dead
5 A#	30	Trunk	I	SSM	2,2	pT3aN1	alive
6 A*	33	Trunk	III	SSM	4	pT4aN0	alive
7	42	Leg	III	NM	2,8	pT3bN0M1	alive

WLE, wide local excision; SLNB, sentinel lymph node biopsy; SSM, superficial spreading melanoma; NM, nodular melanoma; \*early delivery performed at month 8 of gestation; #early delivery performed at month 7 of gestation.

be done in suspicious pigmented lesions.<sup>18</sup> Lidocaine can be safely used as local anesthesia in pregnant women; the addition of small doses of epinephrine is harmless for both mother and fetus.<sup>19,20</sup>

SLNB is not contraindicated during pregnancy, and if the patient is toward the end of pregnancy, it should be discussed, especially when adjuvant therapy is most likely needed. When SLNB is requested, lymphoscintigraphy can be safely carried out after the first trimester, avoiding methylene blue due to its teratogenic effects.<sup>1,14</sup> Before planning surgery and anesthesia, the multidisciplinary team has to be gathered to assess risk/benefit ratio of the procedure.<sup>3,21</sup>

Blood tests and cardiologic examinations are routinely performed to assess anesthesiologic risk for every non-pregnant patient. Gynecologic consultation should be performed before undergoing non-obstetric surgery or before performing any invasive procedure.

The safest time to perform surgery in pregnant women is the second trimester; during the third trimester, the greatest risk is premature labor and delivery due to the stress of surgery. For this reason, intraoperative fetal monitoring is mandatory after 24 weeks of gestation (third trimester).<sup>21</sup>

SLNB and lymphadenectomy are surgeries that often require general anesthesia, depending on where the sentinel node is located. When it comes to surgery and anesthesia during pregnancy, there are known clinical concerns about proceeding with or delaying the surgical procedure.<sup>22</sup> The reported frequency of non-obstetric surgical procedures occurring during gestation is 0.75% to 2% of all pregnancies.<sup>23</sup>

In 2016, the American College of Obstetricians and Gynecologists, together with the American Society of Anesthesiologists, stated that “a pregnant woman should never be denied indicated surgery”. Therefore, it is advisable to postpone elective surgery when possible and perform non-urgent surgery in the second trimester.<sup>24</sup>

Fetal heart rate (FHR) during surgery faces several challenges, such as difficult interpretation and technical difficulties, especially in abdominal surgeries. FHR monitoring still has limitations.<sup>25</sup>

A systematic review investigated the incidence of intraoperative cesarean deliveries that occurred when non-reassuring intraoperative fetal heart rate monitoring (NR-iFHRM) was detected during non-obstetric surgery after 22 weeks of gestation. The review concluded that the available data were insufficient and recommended that further studies are needed.<sup>26</sup>

## Limitations

On one hand, we were able to enroll a significant number of patients with PAM, despite its low incidence. On the other hand, this low incidence also explains the limited number of patients enrolled over the years. Moreover, we focused on the diagnosis and the surgical treatment of PAM, not focusing specifically on the implications of pharmacological/medical treatment. We could recommend a multidisciplinary approach and customized treatment for all patients who have undergone surgery. Further studies are needed to develop international guidelines for the management of a condition as challenging and complex as PAM.

## Conclusions

Recent studies document transient clinical-dermoscopic changes of melanocytic nevi during pregnancy, recommending a close follow-up of these lesions. PAM is a critical diagnosis whose management still needs consensus. The multidisciplinary team is

fundamental for the proper handling of this condition. Child-bearing mothers should be strictly involved during every step and decision, fully informed of the risks and benefits, both maternal and fetal. Psychological support should be taken into account.

This study aimed to show that proper management of preoperative, perioperative, and postoperative steps significantly decreased maternal and fetal complications related to surgery. In our cases, early delivery, at the 7<sup>th</sup> and 8<sup>th</sup> month, did not cause any problems for the babies, who had already reached the acceptable weight and did not need further neonatal intensive assistance.

Surgical treatment should be conducted in centers where both the surgeon and the gynecologist are present.

Our results confirm that pregnancy itself does not seem to be a negative prognostic factor for melanoma.

## References

1. AIOM, Linee guida 2023. Available from: [https://www.iss.it/documents/20126/8403839/LG+127\\_Melanoma\\_agg-ago2023.pdf](https://www.iss.it/documents/20126/8403839/LG+127_Melanoma_agg-ago2023.pdf).
2. Still R, Brennecke S. Melanoma in Pregnancy. *Obstet Med* 2017;10:107-12.
3. Zelin E, Conforti C, Giuffrida R, et al. Melanoma in Pregnancy: Certainties Unborn. *Melanoma Manag* 2020; 7:MMT48.
4. Todd SP, Driscoll MS. Prognosis for Women Diagnosed with Melanoma during, before, or after Pregnancy: Weighing the Evidence. *Int J Womens Dermatol* 2017;3:26-9.
5. Silipo V, De Simone P, Mariani G, et al. Malignant melanoma and pregnancy. *Melanoma Res* 2006;16:497-500.
6. Dadras SS, Lange-Asschenfeldt B, Velasco P, et al. Tumor Lymphangiogenesis Predicts Melanoma Metastasis to Sentinel Lymph Nodes. *Mod Pathol* 2005;18:1232-42.
7. Byrom L, Olsen C, Knight L, et al. Increased Mortality for Pregnancy-Associated Melanoma: Systematic Review and Meta-Analysis. *J Eur Acad Dermatol Venereol* 2015;29:1457-66.
8. Carter TJ, George C, Harwood C, Nathan, P. Melanoma in Pregnancy: Diagnosis and Management in Early-Stage and Advanced Disease. *Eur J Cancer* 2022;166:240-53.
9. Ribero S, Longo C, Dika E, et al. Members of the Melanoma Group of the EORTC. Pregnancy and Melanoma: A European-Wide Survey to Assess Current Management and a Critical Literature Overview. *J Eur Acad Dermatol Venereol* 2017;31:669.
10. Driscoll MS, Martires K, Bieber AK, et al. Pregnancy and Melanoma. *J Am Acad Dermatol* 2016;75:669-78.
11. McCormick A, Peterson E. Cancer in Pregnancy. *Obstet Gynecol Clin North Am* 2018;45:187-200.
12. Amant F, Vandenbroucke T, Verhecke M, et al. Pediatric Outcome after Maternal Cancer Diagnosed during Pregnancy. *N Engl J Med* 2015;373:1824-34.
13. Shiu MH, Schottenfeld D, Maclean B, Fortner JG. Adverse effect of pregnancy on melanoma: a reappraisal. *Cancer* 1976;37:181-7.
14. Garbe C, Amaral T, Peris K, et al. European Consensus-Based Interdisciplinary Guideline for Melanoma. Part 1: Diagnostics: Update 2022. *Eur Cancer* 2022;170:236-55.
15. Daryanani D, Plukker JT, De Hullu JA, et al. Pregnancy and Early-Stage Melanoma. *Cancer* 2003;97:2248-53.
16. Byrom L, Olsen CM, Knight L, et al. Does Pregnancy After a Diagnosis of Melanoma Affect Prognosis? Systematic Review



- and Meta-Analysis. *Dermatol Surg* 2015;41:875-82.
17. Committee Opinion No. 723: Guidelines for Diagnostic Imaging During Pregnancy and Lactation. *Obstet Gynecol* 2017;130:e2106. Erratum in: *Obstet Gynecol* 2018;132:786.
  18. Berk-Krauss J, Liebman TN, Stein JA. Pregnancy and Melanoma: Recommendations for Clinical Scenarios. *Int J Womens Dermatol* 2018;4:113-5.
  19. Kouba DJ, LoPiccolo MC, Alam M, et al. Guidelines for the Use of Local Anesthesia in Office-Based Dermatologic Surgery. *J Am Acad Dermatol* 2016;74:1201-19.
  20. Li JN, Nijhawan RI, Srivastava D. Cutaneous Surgery in Patients Who Are Pregnant or Breastfeeding. *Dermatol Clin* 2019;37:307-17.
  21. Shachar SS, Gallagher K, McGuire K, et al. Multidisciplinary Management of Breast Cancer During Pregnancy. *The Oncologist* 2017;22:324-34.
  22. Broer N, Buonocore S, Goldberg C, et al. Proposal for the Timing of Management of Patients with Melanoma Presenting during Pregnancy. *J Surg Oncol* 2012;106:36-40.
  23. Ni Mhuireachtaigh R, O’Gorman DA. Anesthesia in Pregnant Patients for Nonobstetric Surgery. *J Clin Anesth* 2006;18:60-6.
  24. Committee Opinion No. 696: Nonobstetric Surgery During Pregnancy. *Obstet Gynecol* 2017;129:777-8.
  25. Higgins MF, Pollard L, McGuinness SK, Kingdom JC. Fetal Heart Rate Monitoring in Nonobstetric Surgery: A Systematic Review of the Evidence. *Am J Obstet Gynecol MFM* 2019;1:100048.
  26. Po’ G, Olivieri C, Rose CH, et al. Intraoperative Fetal Heart Monitoring for Non-Obstetric Surgery: A Systematic Review. *Eur J Obstet Gynecol Reprod Biol* 2019;238:12-19.