

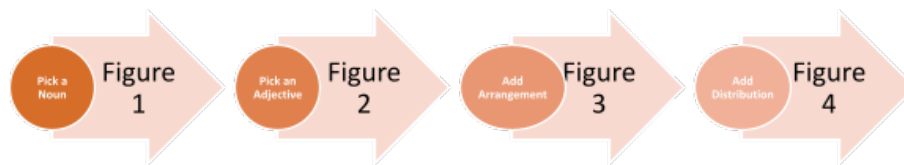
## Grammatical approach to describing skin lesions: framework and assessment

Adam Cardenas, Emilie A. Foltz, Simi Cadmus, Dayna Diven

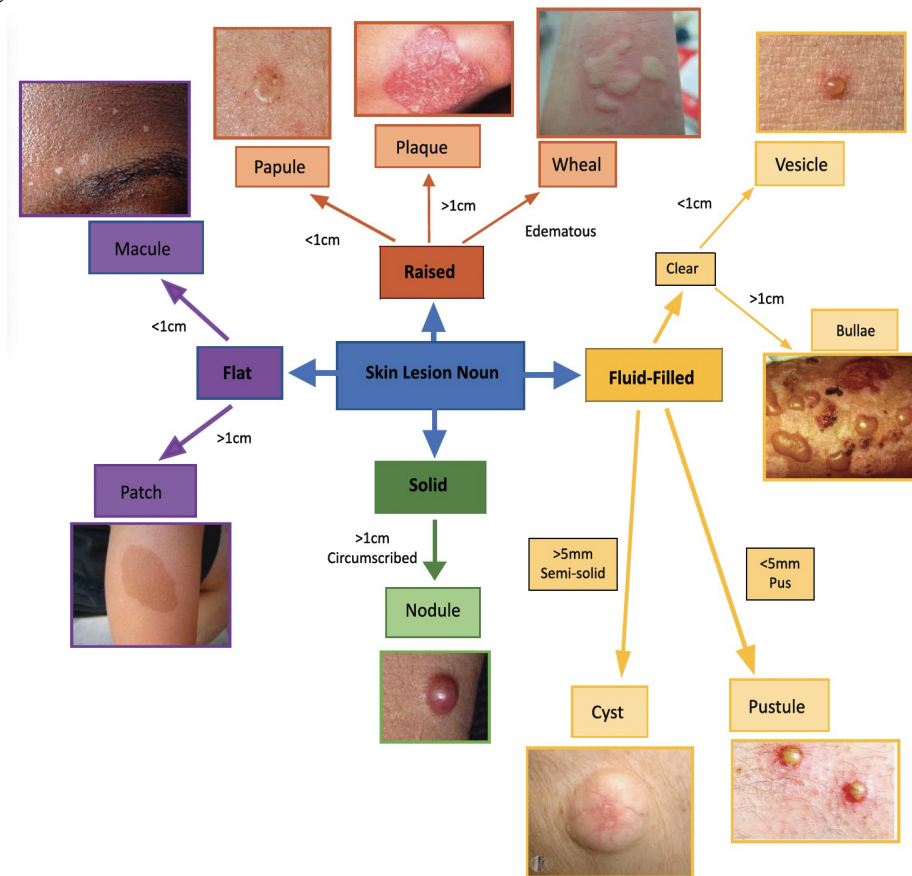
### SUPPLEMENTARY MATERIAL

**Appendix 1.** Learning materials offered to survey participants.

**Process Figure:** general approach broken down into simplified components.



**Noun:** selecting the foundation of a lesion.



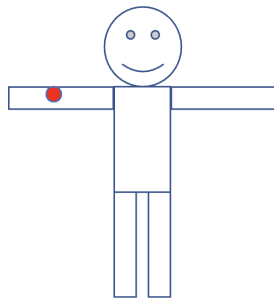
**Adjective:** describing key characteristics of a lesion.

Shape
<ul style="list-style-type: none"><li>•Round/circular</li><li>•Oval</li><li>•Annular - ring shaped +/- central clearing</li><li>•Arcuate - arc</li><li>•Targetoid</li><li>•Umbilicated</li><li>•Flat-topped</li></ul>

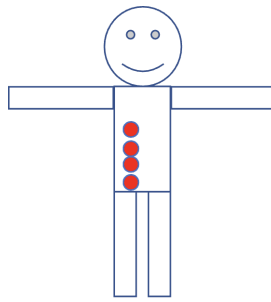
Color
<ul style="list-style-type: none"><li>•Pale pink</li><li>•Pink</li><li>•Red - erythematous</li><li>•Purple/violaceous</li><li>•Blue</li><li>•Yellow</li><li>•Black</li><li>•Brown/hyperpigmented</li><li>•White/hypopigmented/depigmented</li><li>•Shiny</li></ul>

Surface Change
<ul style="list-style-type: none"><li>•Scale - thick or thin</li><li>•Crust - scabbed</li><li>•Lichenification - thickened with accentuated skin lines</li><li>•Excoriation - scratched</li><li>•Erosion - superficial</li><li>•Ulcer - deep</li><li>•Eschar - dead tissue</li><li>•Atrophy - thin</li><li>•Character - Soft, Firm, Well-demarcated</li></ul>

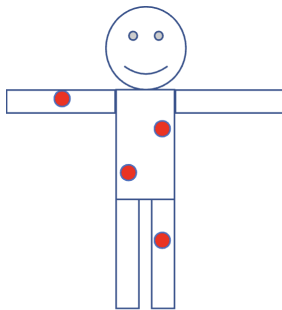
**Arrangement:** describing skin lesions' location in relation to each other.



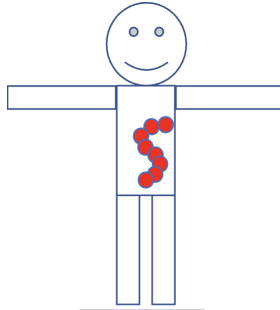
Isolated/Localized



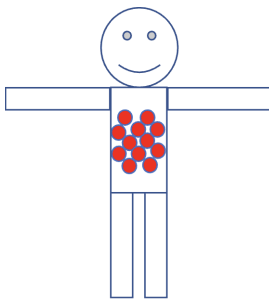
Linear



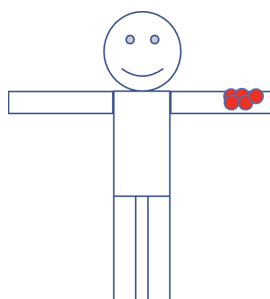
Scattered



Serpiginous

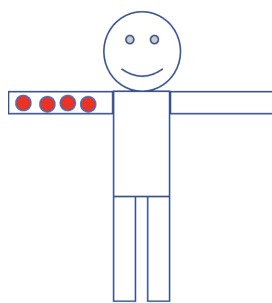


Reticular (net-like)

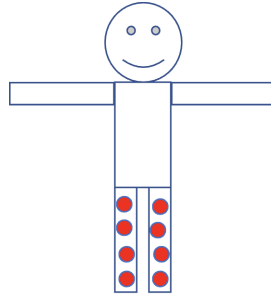


Grouped/Clustered

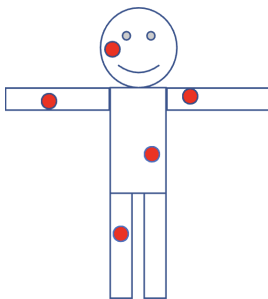
**Distribution:** describing skin lesion(s) location on the entire body.



Unilateral



Bilateral



Generalized


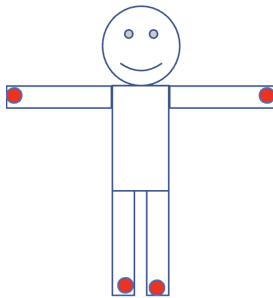
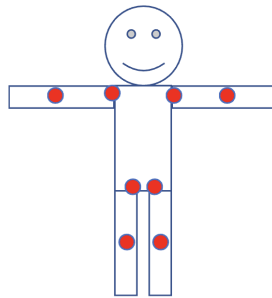



Photo-distributed



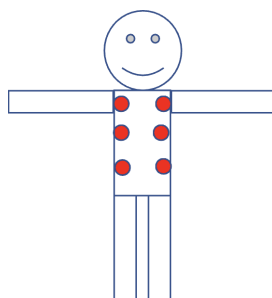
Acral



Flexural



Dermatomal



Symmetric